

Spectral Domain Optical Coherence Tomography (SD-OCT) Features of Idiopathic Juxtafoveal Retinal Telangiectasia

Shailaja S Bhat¹, Shrinivas M. Ganagi², Sarita R J Gonsalves³, Undrakonda Vivekanand⁴,
Yogish Kamath⁵

^{1,5}Department Of Ophthalmology, Kasturba Medical College ,MANIPAL, ²Department Of Ophthalmology DM WIMS, Meppadi district, Wyanad Kerala, ³Department of ophthalmology Father Muller Medical college, Mangalore, ⁴Department Of Ophthalmology, Alluri Sitarama Raju Academy Of Medical Sciences, Eluru, Andhra Pradesh.

I. Introduction

Idiopathic juxtafoveolar telangiectasia (IJT) is a descriptive term for various disease entities presenting with incompetence of the capillary network affecting only the juxtafoveolar region of one or both eyes. Based on the biomicroscopic and angiographic features Gass and Blodi have classified IJT into 3 groups with two subgroups in each (A and B), based on demographic difference and clinical severity. Group I was congenital, predominantly presenting in males with unilateral telangiectasis and macular edema. Group II was acquired, idiopathic, bilateral telangiectasis with atrophy of the fovea. Group III is characterized by progressive obliteration of the perifoveal capillary network associated with occlusive vascular retinal diseases. Gass-Blodi proposed a staging system where they divided IJT type 2A into 5 stages¹. Yannuzzi et al simplified the five stages of group IIA proposed by Gass and Blodi into two distinct stages nonproliferative and proliferative stage. Optical coherence tomography (OCT) is a non-invasive retinal imaging technique that allows evaluation of retinal structures in vivo. Spectral domain OCT has a resolution of 5 microns allows better delineation of retinal structural abnormalities in patients with group 2a IJT².

Aim:

- 1) To describe the SD-OCT features of idiopathic juxtafoveal telangiectasia (IJT) type 2A.
- 2) To correlate the OCT features with visual acuity.

II. Materials And Methods

Retrospective analysis of the medical records of 16 eyes of 8 patients with the diagnosis of IJT2A was done. Data regarding age, gender, laterality, presence of diabetes mellitus, best corrected visual acuity (BCVA) in each eye was collected. Fundus photographs, FFA and OCT images were analysed. Spearman's coefficient of rank correlation (r₂) was determined between best corrected visual acuity and central foveal thickness. A logistic regression analysis was performed to see the association between IS-OS disruption and BCVA. OCT features analysed included central foveal thickness, IS-OS disruption in the foveal region, IS-OS disruption in the parafoveal region, foveal cystoid, parafoveal cystoid, ILM druse, intra retinal blood vessels, RPE hyperplasia and presence of CNVM.

III. Results

We studied 16 eyes of 8 patients. The average age was 59.75 years. Male : female ratio was 5:3. 2 patients had a history of diabetes mellitus but none had diabetic retinopathy changes. Mean central foveal thickness was 201.5 microns. The standard deviation was 20.45. The range was 159-233 microns.

BCVA ranged from 6/6, N6 to 6/36, N36. Spearman's coefficient of rank correlation (r₂) was determined between best corrected visual acuity and central foveal thickness: "r" value : 0.69 Which signified high correlation with marked relationship.

BCVA table:

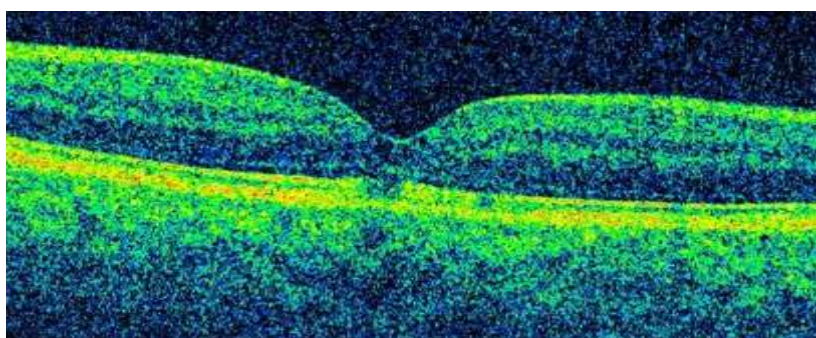
RESULTS

Sl.NO.	OD			OS		
	VA-Distance	NV	CFT	VA-Distance	NV	CFT
1	6/24	N 24	229	6/36	N24	222
2	6/9	N6	233	6/9	N8	199
3	6/18	N16	194	6/12	N 10	195
4	6/6	N6	219	6/18	N10	215
5	6/6	N6	210	6/24	N10	167
6	6/6	N6	187	6/9	N8	194
7	6/36	N24	159	6/9	N6	195
8	6/9	N8	211	6/18	N12	195

IS-OS Disruption in the foveal region:

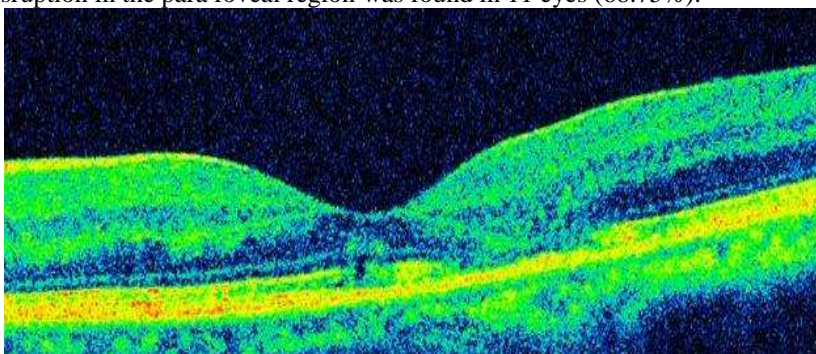
Disruption of the inner segment - outer segment (IS-OS) junction at the fovealcentre and severity of vision loss was found in 9 eyes (56.25%)

An association between disruption of IS-OS junction at the fovealcentre and severity of vision loss was found (Odds ratio =19.72 {binary logistic regression analysis})



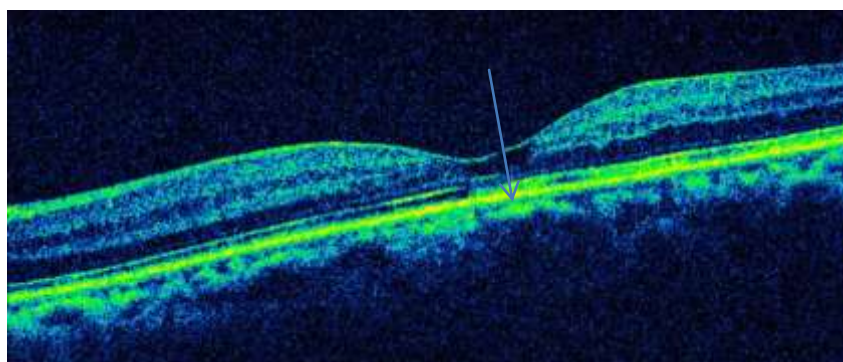
IS-OS disruption in the para foveal region:

IS-OS junction disruption in the para foveal region was found in 11 eyes (68.75%).



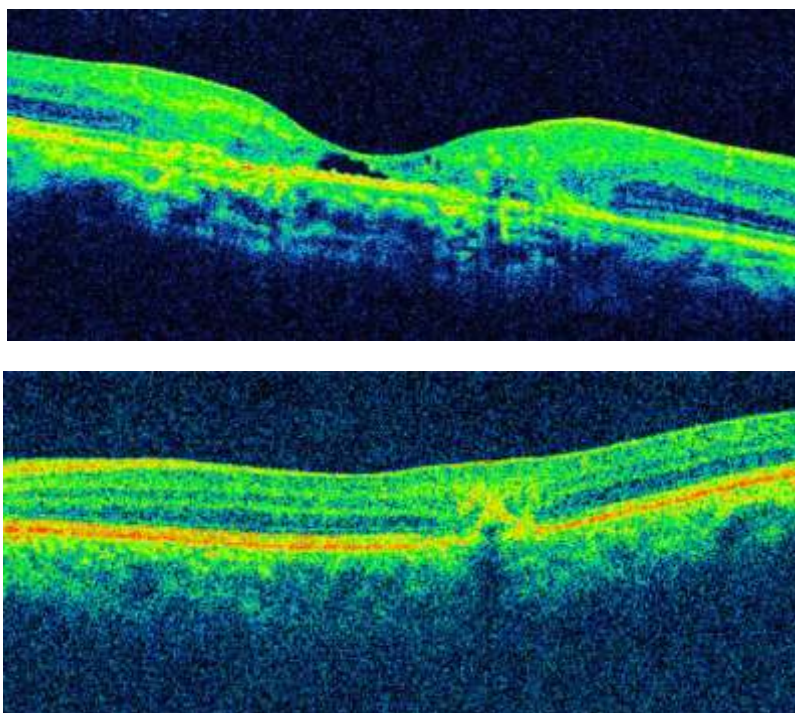
Internal limiting membrane drape:

At the foveola, inner retinal cyst appears as loss of tissue with the ILM spanning across it and draping over it. This is called as ILM drape and is considered specific for IJRT 2A. Internal limiting membrane (ILM) drape was seen in 7eyes (43.75%)



The other OCT features studied included:

Foveal and parafovealcystoids ,Fluid in the outer retina ,Large intraretinal blood vessels ,Hyper reflective plaque,CNVM was not seen in any of the eyes.



RESULTS

OCT FEATURES	EYES (%)
IS-OS DISRUPTION SUBFOVEAL	9 (56.2)
IS-OS DISRUPTION PARAFOVEAL	11 (68.8)
FOVEAL CYSTOID	2 (12.5)
PARAFOVEAL CYSTOID	3 (18.8)
ILM DRAPE	7 (43.8)
IRET BL VESSEL	2 (12.5)
RPE HYPERPLASIA	3 (18.8)
CNVM	NII
FLUID -OUT RET	2 (12.5)
FLUID -INNER	NII

IV. Discussion

In corroboration with previous studies in our series intraretinal cysts were not associated with retinal thickening and did not correspond to the areas of hyperfluorescence on FFA .They may be due to loss of tissue and not due to exudation³.

IS –OS junction is considered an important indicator of integrity and Loss/disruption of the IS-OS junction may be secondary to the degeneration of the neurosensory retina⁴ .IS-OS junction disruption in the subfoveolar area was associated with reduced visual acuity.

V. Conclusion

- 1) SD-OCT is useful in the diagnosis of IJT.
- 2) Loss of the photoreceptor layer integrity is usually associated with vision loss.

References

- [1]. Gass JD, Blodi BA. Idiopathic juxtafoveal retinal telangiectasis. Update of classification and follow-up study. *Ophthalmology* 1993; 100: 1536 –1546.
- [2]. Paunescu LA, Ko TH, Duker JS, Chan A, Drexler W, Schuman JS, et al. Idiopathic juxtafoveal retinal telangiectasis: new findings by ultrahigh-resolution optical coherence tomography. *Ophthalmology* 2006; 113: 48-57.
- [3]. Ferdinando B, Erdinando B, Intergrated clinical evaluation of IJRT type 2 A , *Retina* 2010 ; 30: 317-326.
- [4]. Sawsan R., Nowilaty, Hanan N. Al-Shamsi, Wajeeha Al-Khars. *Middle East African Journal of Ophthalmology* ; 2010 :17(3) 224-241.